PLEXUS DIAGNOSTICS
A Complete Pathology Laboratory

Dr. Satish Patel
M.D.D.C.P.M.B.
(Path. & Bact)

A-113, First Floor, Roseville Sky, Opp. Puskar Icon, Nikol - Naroda Road, Ahmedabad. **Mob. 97259 08448**

3:10 PM

Patient's Name	: **Pankaj B Thakker**	Ref. No.	: 3219
Referred by	: C/o. Plexus Heart Surgery Centre @ Nikol	Age	: 50 Years
Date	: 30/12/2024	Sex	: Male

HEMOGRAM

Test Name	Result	Units	Biological Reference Interval
Hemoglobin :	15.0	g/dl	[13.0-18.0]
Total RBC Count :	5.83	mill/cmm	[4.7-6.0]
Total WBC Count :	**10,300**	/cmm	[4000-10000]
Platelet Count :	**1,25,000**	/cmm	150000-450000
Blood Indices			
P.C.V :	44.9	%	[42-52]
M.C.V. :	77.0	femtolitre	[78-100]
M.C.H. :	25.8	pg	[27-31]
M.C.H.C. :	33.5	g/dl	[32-36]
Differential WBC Count			
Polymorphs :	60	%	[60 - 70]
Lymphocytes :	35	%	[20 - 40]
Eosinophils :	02	%	[1 - 4]
Monocytes :	03	%	[2 - 6]
Basophils :	00	%	[0 - 1]

Smear Study

RBCs :	RBCs are normocytic,normochromic.
WBCs :	WBCs series shows leucocytosis.
Platelets :	Platelets are reduced in number.
PS For MP :	No any parasites seen.

PLEXUS HEART SURGERY CENTER
DR. JAYDIP RAMANI
Center of Minimal Invasive Cardiac Surgery

PLEXUS DIAGNOSTICS
A Complete Pathology Laboratory

Dr. Satish Patel
M.D.D.C.P.M.B.
(Path. & Bact)

A-113, First Floor, Roseville Sky, Opp. Puskar Icon, Nikol - Naroda Road, Ahmedabad. **Mob. 97259 08448**

Patient's Name	**: Pankaj B Thakker**	Ref. No.	: 3219
Referred by	: C/o. Plexus Heart Surgery Centre @ Nikol	Age	: 50 Years
Date	: 30/12/2024	Sex	: Male

URINE EXAMINATION

PHYSICAL EXAMINATION:

Volume	- 20 ml
Colour	- Pale Yellow
Blood	- Absent
Appearance	- Clear
Deposit	- Absent

CHEMICAL EXAMINATION:

Protein	- Trace
Glucose	- Absent
Bile Salts	- Absent
Bile Pigments	- Absent
Reaction	- Acidic

MICROSCOPIC EXAMINATION: [After centrifugation at 2000 r.p.m. for 5 minutes]

Pus Cells	- 2-4	/H.P.F
Red Cells	- Absent	/H.P.F.
Epithelial Cells	- 1-2	/H.P.F.
Casts	- Absent	
Crystals	- Absent	
Yeast Cells	- Absent	
Trichomonas Vag.	- Absent	
Bacteria	- Absent	

PLEXUS HEART SURGERY CENTER
DR. JAYDIP RAMANI
Cardiac Surgery
Center of Minimally Invasive

PLEXUS DIAGNOSTICS
A Complete Pathology Laboratory

Dr. Satish Patel
M.D.D.C.P.M.B.
(Path. & Bact)

A-113, First Floor, Roseville Sky, Opp. Puskar Icon, Nikol - Naroda Road, Ahmedabad. **Mob. 97259 08448**

Patient's Name	**: Pankaj B Thakker**	Ref. No.	: 3219
Referred by	: C/o. Plexus Heart Surgery Centre @ Nikol	Age	: 50 Years
Date	: 30/12/2024	Sex	: Male

PRE - OPERATIVE MAJOR

Test Name	Result	Units	Biological Reference Interval
HIV I & II	: Non Reactive		Non Reactive
HbsAg	: Non Reactive		Negative
Random Blood Sugar	: 110.0	Mg%	80.0 to 140.0
Creatinine	: 1.29	mg/dl	0.6 - 1.4
S.G.P.T	: 28.0	U/L	0 - 40
Bilirubin (Total)	: 0.6	mg/dl	0.3 - 1.2
Bilirubin (Direct)	: 0.4	mg/dl	0 - 0.6
Bilirubin (Indirect)	: 0.2	mg/dl	0 - 0.8
Serum Sodium	: 144.9	mmol /L	[137 - 145]
Serum Potassium	: 4.02	mmol/L	[3.5 - 5.1]
Prothrombin Time (Control)	: 14.00 Sec.		[12 - 14]
Prothrombin Time (Patient)	: 15.00 Sec.		
INR	: 1.07		
Blood Group			
ABO RH TYPE	: "A" "POSITIVE"		

PLEXUS HEART SURGERY CENTER
DR. JAYDIP RAMANI
Center of Minimal Invasive Cardiac Surgery

PLEXUS
DIAGNOSTICS
A Complete Pathology Laboratory

Dr. Satish Patel
M.D.D.C.P.M.B.
(Path. & Bact)

A-113, First Floor, Roseville Sky, Opp. Puskar Icon, Nikol - Naroda Road, Ahmedabad. **Mob. 97259 08448**

Patient's Name	: **Pankaj B Thakker**	Ref. No.	: 3219
Referred by	: C/o. Plexus Heart Surgery Centre @ Nikol	Age	: 50 Years
Date	: 30/12/2024	Sex	: Male

HCV

Test Name	Result
HCV (Hepatitis C Virus) : (Method: Immunochromatography)	Non Reactive

Note

1. Limit of detection for all genotypes is a viral load of 500 IU/mL. No genotype detected if the viral load is below the limit of detection.
2. Indeterminate result indicates inability to calssify the sample provided due to presence of inhibitors. Repeat sample is recommended.
3. This is an in house developed assay, Sequencing of the 5' UTR elucidates the genotype of the virus.

Interpretation

HCV genotyping assay determines the Genotypes 1,2,3,4,5 & 6 and their subtypes in positive cases, HCV genotype 1 is more diffucult to treat than Genotypes 2 & 3 and causes more severe liver disease. This test should not be used for screening of blood products or as a diagnostic test to confirm the presence of HCV infection.

Comments

HCV is an RNA virus of the the Flavivirus group transmitted in 60% of the cases due to drug abuse. Other modes of transmission seen are following accidental needle punctures in health care workers, dialysis patients and rarely from mother to infant. Sexual transimission accounts for 10% of cases. Chronic infection with HCV occurs in about 85% of infected individuals leading to fibrosis of the liver and cirrhosis in about 20% of these patients. Risk for Hepatocellular carcinoma in a patient with chronic HCV is 1-5% after 20 years.

Uses

This test is useful in predicting the prognosis is patients with chronic Hepatitis C infection and to determine the course of therapy.

PLEXUS HEART SURGERY CENTER
DR. JAYDIP RAMANI
Cardiac Surgery
Center of Minimally Invasive

PLEXUS DIAGNOSTICS
A Complete Pathology Laboratory

Dr. Satish Patel
M.D.D.C.P.M.B.
(Path. & Bact)

A-113, First Floor, Roseville Sky, Opp. Puskar Icon, Nikol - Naroda Road, Ahmedabad. **Mob. 97259 08448**

Patient's Name	: **Pankaj B Thakker**	Ref. No.	: 3230
Referred by	: C/o. Plexus Heart Surgery Centre @ Nikol	Age	: 50 Years
Date	: 31/12/2024	Sex	: Male

HEMOGRAM

Test Name	Result	Units	Biological Reference Interval
Hemoglobin :	14.5	g/dl	[13.0-18.0]

BIOCHEMICAL TESTS

Test Name	Result	Units	Biological Reference Interval
Potassium :	4.07	mEq/L	3.5 - 5.1

PLEXUS HEART SURGERY CENTER
DR. JAYDIP RAMANI
Cardiac Surgery

PLEXUS DIAGNOSTICS
A Complete Pathology Laboratory

Dr. Satish Patel
M.D.D.C.P.M.B.
(Path. & Bact)

A-113, First Floor, Roseville Sky, Opp. Puskar Icon, Nikol - Naroda Road, Ahmedabad. **Mob. 97259 08448**

Patient's Name	: **Pankaj B Thakker**	Ref. No.	: 3234
Referred by	: C/o. Plexus Heart Surgery Centre @ Nikol	Age	: 50 Years
Date	: 31/12/2024	Sex	: Male

HEMOGRAM

Test Name	Result	Units	Biological Reference Interval
Hemoglobin :	13.6	g/dl	[13.0-18.0]

BIOCHEMICAL TESTS

Test Name	Result	Units	Biological Reference Interval
Potassium :	3.99	mEq/L	3.5 - 5.1

PLEXUS HEART SURGERY CENTER
DR. JAYDIP RAMANI
Cardiac Surgery
Minimal Invasive

PLEXUS DIAGNOSTICS
A Complete Pathology Laboratory

Dr. Satish Patel
M.D.D.C.P.M.B.
(Path. & Bact)

A-113, First Floor, Roseville Sky, Opp. Puskar Icon, Nikol - Naroda Road, Ahmedabad. **Mob. 97259 08448**

9:00 AM

Patient's Name	: **Pankaj B Thakker**	Ref. No.	: 3238
Referred by	: C/o. Plexus Heart Surgery Centre @ Nikol	Age	: 50 Years
Date	: 01/01/2025	Sex	: Male

HEMOGRAM

Test Name	Result	Units	Biological Reference Interval
Hemoglobin :	14.4	g/dl	[13.0-18.0]
Total RBC Count :	5.36	mill/cmm	[4.7-6.0]
Total WBC Count :	**15,000**	/cmm	[4000-10000]
Platelet Count :	1,52,000	/cmm	150000-450000
Blood Indices			
P.C.V :	42.4	%	[42-52]
M.C.V. :	79.1	femtolitre	[78-100]
M.C.H. :	26.9	pg	[27-31]
M.C.H.C. :	34.0	g/dl	[32-36]
Differential WBC Count			
Polymorphs :	75	%	[60 - 70]
Lymphocytes :	20	%	[20 - 40]
Eosinophils :	03	%	[1 - 4]
Monocytes :	02	%	[2 - 6]
Basophils :	00	%	[0 - 1]

Smear Study

RBCs :	RBCs are normocytic,normochromic.
WBCs :	WBCs series shows leucocytosis.
Platelets :	Platelets are adequate in number & normal in morphology.
PS For MP :	No any parasites seen.

BIOCHEMICAL TESTS

Test Name	Result	Units	Biological Reference Interval
Potassium :	4.18	mEq/L	3.5 - 5.1

PLEXUS HEART SURGERY CENTER
DR. JAYDIP RAMANI
Cardiac Surgery
Center of Minimal Invasive

PLEXUS DIAGNOSTICS
A Complete Pathology Laboratory

Dr. Satish Patel
M.D.D.C.P.M.B.
(Path. & Bact)

A-113, First Floor, Roseville Sky, Opp. Puskar Icon, Nikol - Naroda Road, Ahmedabad. **Mob. 97259 08448**

Patient's Name	: **Pankaj B Thakker**	Ref. No.	: 3249
Referred by	: C/o. Plexus Heart Surgery Centre @ Nikol	Age	: 50 Years
Date	: 01/01/2025	Sex	: Male

BIOCHEMICAL TESTS

Test Name	Result	Units	Biological Reference Interval
Potassium :	3.65	mEq/L	3.5 - 5.1

PLEXUS HEART SURGERY CENTER
DR. JAYDIP RAMANI
Cardiac Surgery
Center of Excellence

PLEXUS DIAGNOSTICS
A Complete Pathology Laboratory

Dr. Satish Patel
M.D.D.C.P.M.B.
(Path. & Bact)

A-113, First Floor, Roseville Sky, Opp. Puskar Icon, Nikol - Naroda Road, Ahmedabad. **Mob. 97259 08448**

9:20 AM

Patient's Name	: **Pankaj B Thakker**	Ref. No.	: 3251
Referred by	: C/o. Plexus Heart Surgery Centre @ Nikol	Age	: 50 Years
Date	: 02/01/2025	Sex	: Male

HEMOGRAM

Test Name	Result	Units	Biological Reference Interval
Hemoglobin :	13.0	g/dl	[13.0-18.0]
Total RBC Count :	5.03	mill/cmm	[4.7-6.0]
Total WBC Count :	**14,500**	/cmm	[4000-10000]
Platelet Count :	1,70,000	/cmm	150000-450000
Blood Indices			
P.C.V :	39.9	%	[42-52]
M.C.V. :	79.2	femtolitre	[78-100]
M.C.H. :	27.2	pg	[27-31]
M.C.H.C. :	34.4	g/dl	[32-36]
Differential WBC Count			
Polymorphs :	75	%	[60 - 70]
Lymphocytes :	20	%	[20 - 40]
Eosinophils :	03	%	[1 - 4]
Monocytes :	02	%	[2 - 6]
Basophils :	00	%	[0 - 1]

Smear Study

RBCs :	RBCs are normocytic,normochromic.
WBCs :	WBCs series shows leucocytosis.
Platelets :	Platelets are adequate in number & normal in morphology.
PS For MP :	No any parasites seen.

BIOCHEMICAL TESTS

Test Name	Result	Units	Biological Reference Interval
Potassium :	3.80	mEq/L	3.5 - 5.1

PLEXUS HEART SURGERY CENTER
DR. JAYDIP RAMANI
Cardiac Surgery
Center of Minimal Invasive

PLEXUS DIAGNOSTICS
A Complete Pathology Laboratory

Dr. Satish Patel
M.D.D.C.P.M.B.
(Path. & Bact)

A-113, First Floor, Roseville Sky, Opp. Puskar Icon, Nikol - Naroda Road, Ahmedabad. **Mob. 97259 08448**

Patient's Name	: **Pankaj B Thakker**	Ref. No.	: 3263
Referred by	: C/o. Plexus Heart Surgery Centre @ Nikol	Age	: 50 Years
Date	: 02/01/2025	Sex	: Male

BIOCHEMICAL TESTS

Test Name	Result	Units	Biological Reference Interval
Potassium :	**3.29**	mEq/L	3.5 - 5.1

PLEXUS HEART SURGERY CENTER
DR. JAYDIP RAMANI
Cardiac Surgery
Center of Minimally Invasive

PLEXUS DIAGNOSTICS
A Complete Pathology Laboratory

Dr. Satish Patel
M.D.D.C.P.M.B.
(Path. & Bact)

A-113, First Floor, Roseville Sky, Opp. Puskar Icon, Nikol - Naroda Road, Ahmedabad. **Mob. 97259 08448**

9:50 AM

Patient's Name	: **Pankaj B Thakker**	Ref. No.	: 3266
Referred by	: C/o. Plexus Heart Surgery Centre @ Nikol	Age	: 50 Years
Date	: 03/01/2025	Sex	: Male

HEMOGRAM

Test Name	Result	Units	Biological Reference Interval
Hemoglobin :	13.0	g/dl	[13.0-18.0]

BIOCHEMICAL TESTS

Test Name	Result	Units	Biological Reference Interval
Potassium :	3.70	mEq/L	3.5 - 5.1

PLEXUS HEART SURGERY CENTER
DR. JAYDIP RAMANI
Cardiac Surgery
Center of Excellence

PLEXUS DIAGNOSTICS
A Complete Pathology Laboratory

Dr. Satish Patel
M.D.D.C.P.M.B.
(Path. & Bact)

A-113, First Floor, Roseville Sky, Opp. Puskar Icon, Nikol - Naroda Road, Ahmedabad. **Mob. 97259 08448**

Patient's Name	: **Pankaj B Thakker**	Ref. No.	: 3284
Referred by	: C/o. Plexus Heart Surgery Centre @ Nikol	Age	: 50 Years
Date	: 03/01/2025	Sex	: Male

BIOCHEMICAL TESTS

Test Name	Result	Units	Biological Reference Interval
Potassium :	3.97	mEq/L	3.5 - 5.1

PLEXUS HEART SURGERY CENTER
DR. JAYDIP RAMANI
Cardiac Surgery
Center of Minimally Invasive Surgery

UHID :H1667 IPID :IP/433
PANKAJ B THAKKAR
Male / 50 Yrs
DELUXE ROOM
7046306763 9879205867
DR. JAYDIP RAMANI
GENERAL 30/12/2024

2024-12-30 13:43:11

Vent. Rate	58 bpm
PR Interval	116 ms
QRS Duration	102 ms
QT/QTc Interval	420/417 ms
P/QRS/T Axes	13/10/59 deg
QTc:Hodges	

Sinus rhythm
Lead(s) unsuitable for analysis: V
--- Interpretation made without knowing patient's gender/age ---
Widespread ST-T abnormality may be due to myocardial ischemia

Abnormal ECG

Unconfirmed Diagnosis.

Pankaj bhai 30/12/24 13:43 pm

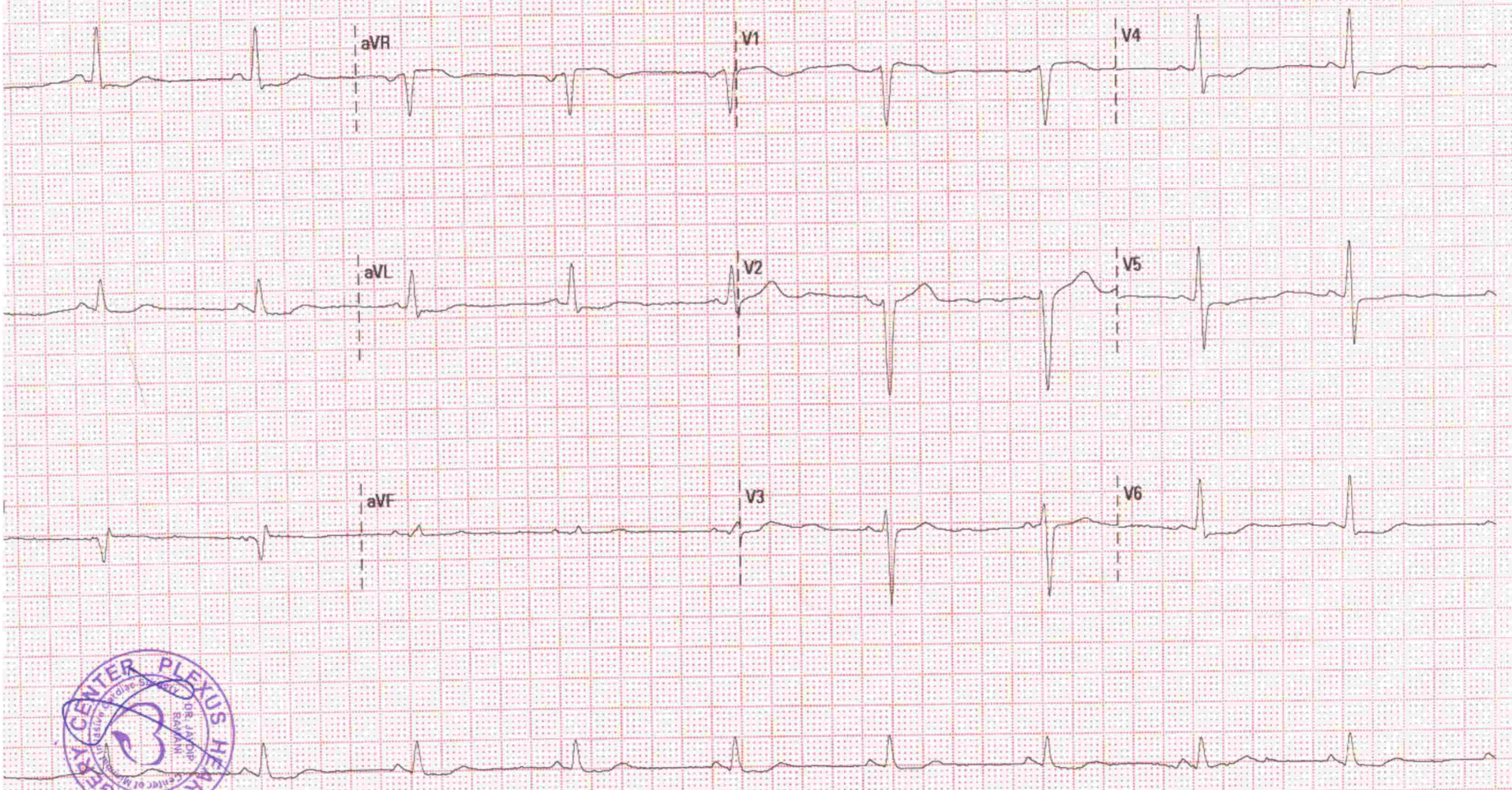

PLEXUS HEART CENTER SURGERY

25 mm/s 10 mm/mV 50 Hz BDR 20 Hz Plexus Cardiac Heart Hospital 02.10.00/V28.4.1 SN:FN-37043738

MICRO MED

PLEXUS
HEART SURGERY CENTER
Center of Minimal Invasive Cardiac Surgery

DR. JAYDIP RAMANI
MBBS, MS, M.Ch.
Consultant Cardio Thoracic
& Vascular Surgeon
Minimal Invasive Cardiac Surgeon

Date:

X-RAY CHEST PA VIEW

DATE: 30/12/2024

PATIENT NAME: MR. PANKAJ B. THAKKAR
AGE: 51/ MALE
DR: DR. JAYDIP RAMANI

- Both lung fields appear clear.
- No evidence of mass lesion is seen.
- Cardiac size appears normal.
- Both CP angles and both domes of diaphragm appear normal.
- Bony thorax under vision appears normal.

PLEXUS HEART SURGERY CENTER
DR. JAYDIP RAMANI
Center of Minimal Invasive Cardiac Surgery

DR. JAYDIP RAMANI.
M.B.B.S, M.S., M. Ch
Cardio vascular & Thoracic Surgeon.